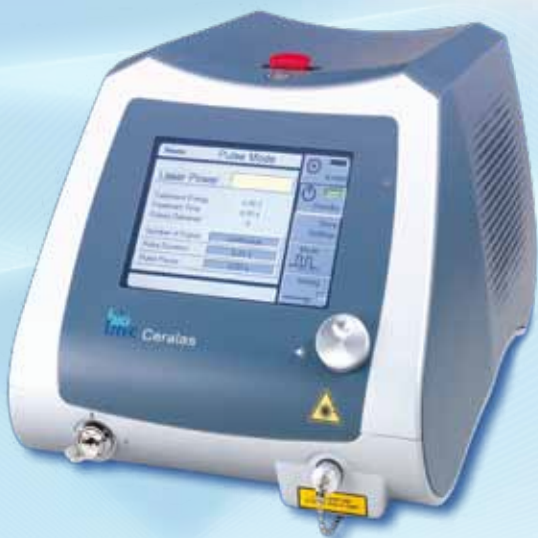

EVOLVE™

EVOLVE™ in Surgery

Laser Solutions in Coloproctology

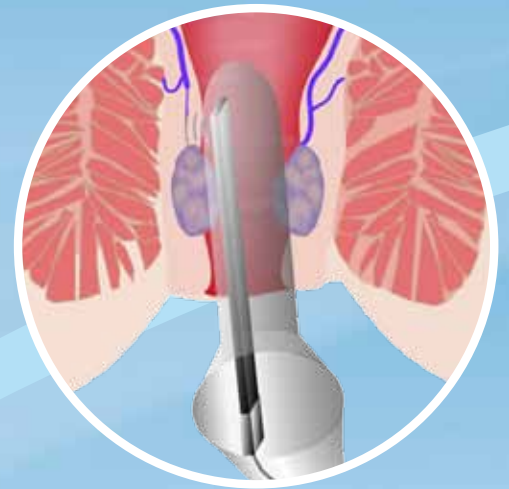
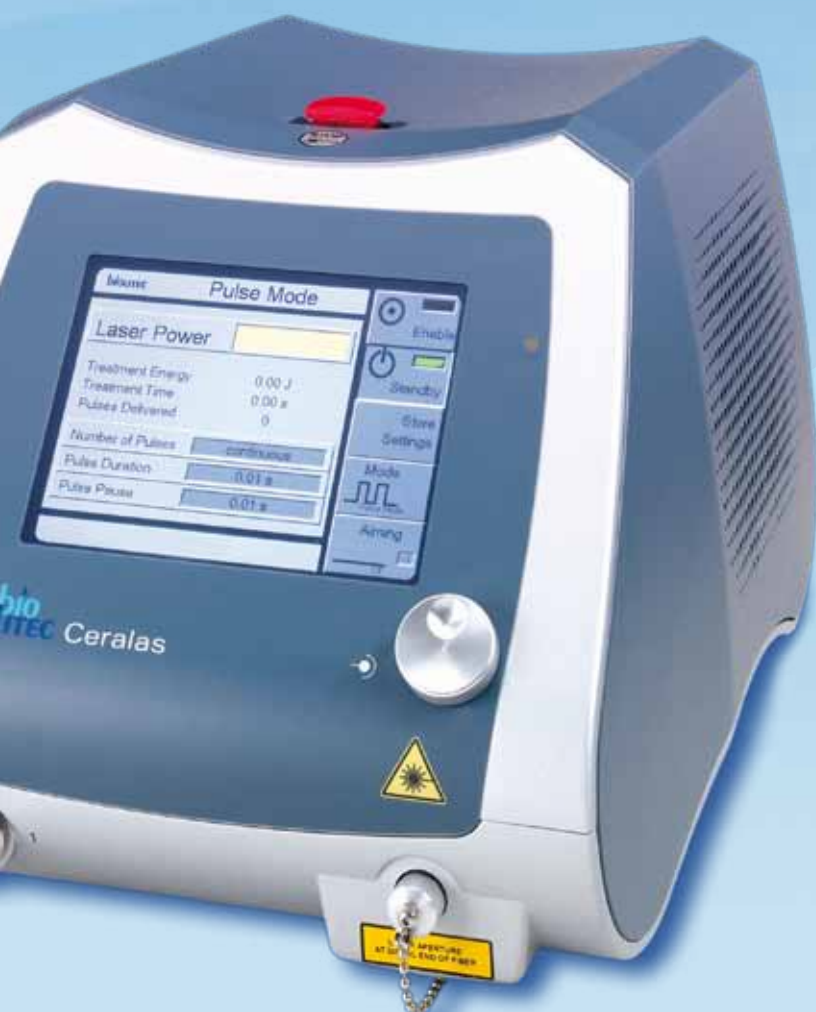

bio®
LITEC
biomedical technology

EVOLVE™ in Surgery

Our Laser Solutions in Coloproctology

HeLP™ Ambulatory Laser Treatment of Hemorrhoids

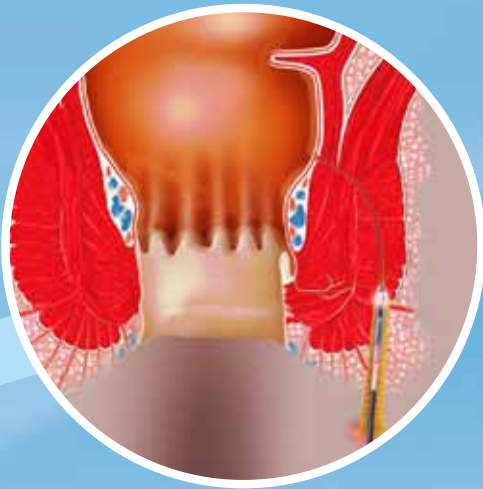

HeLP™ - for hemorrhoids

HeLP™ is the least invasive of surgical procedures for hemorrhoidal dearterialization for curing hemorrhoids. HeLP™ uses an integral procedure kit specially designed by biolitec to achieve a treatment that is fast, painless, and above all, simple and reproducible by the surgeon.

FiLaC

Fistula-tract Laser Closure

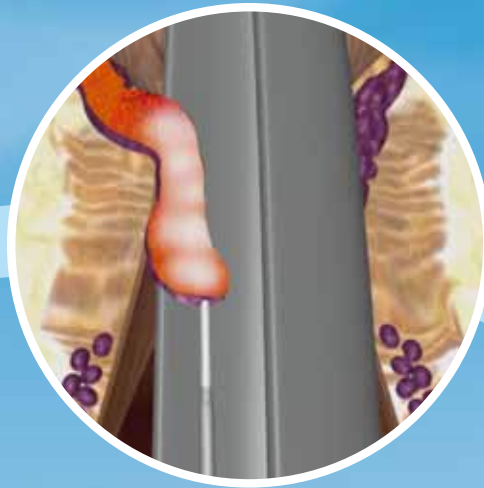

FiLaC – for anal fistulas

The aim is to gently remove the fistula tract without damaging the sphincter. Thus, any parts of the muscle are preserved to a maximum and incontinence is avoided.

LHP

Laser Hemorrhoidoplasty



LHP - for hemorrhoids

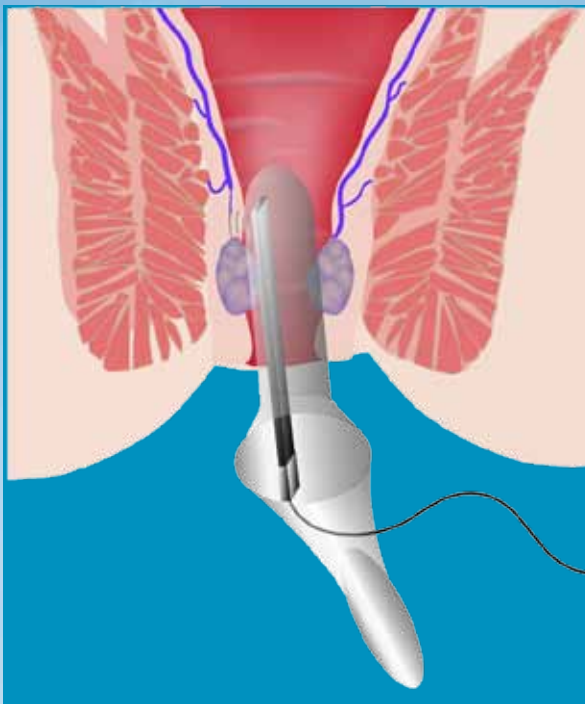
This approach is used for advanced hemorrhoids under appropriate anesthesia. The energy of the laser is inserted centrally through a radial emitting fiber into the hemorrhoidal node.

Safe · Effective · Fast · Painless

Hemorrhoid treat

Doppler assisted laser ligation of the arteries

2nd and 3rd degree



The perfect relief/solution for patients fearing invasive painful surgical or semi-surgical techniques in this delicate matter. Especially if the patients are fed up with rubber band or sclerosation this easy and accurate application is the right alternative. It is an ambulatory approach and serves you with fast procedures needing just one intervention.

The HeLP™ proctoscope is designed for easy insertion into the anal canal. It consists of a working channel containing the disposable HeLP™ Doppler probe, which identifies the branches of the superior hemorrhoidal arteries above the dentate line.

The laser energy is then applied to each of the sub mucosal branches using the handpiece of the special HeLP™ fiber. Laser photocoagulation of the branches closes the superior hemorrhoidal arteries and decreases the pressure in the hemorrhoidal piles. In this way the arterio-venous flow is modified leading to withdrawal of the piles on subsequent days and weeks.



Combination

You might as well combine both approaches to optimize patients benefit. By previously closing the feeding arteries bleedings will be

HELP™ tments

Laser hemorrhoido- plasty (LHP)

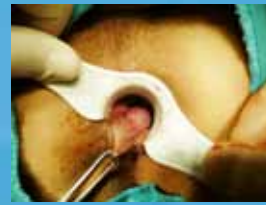3rd and 4th degree

If immediate removal/reduction of the hemorrhoidal cushion is indicated (no matter if it is segmental or circular) this therapy will provide you with an improved patient outcome especially regarding pain and down times compared to conventional surgical proceeding. Under proper local or general anesthesia the controlled laser energy deposition obliterates the nodes from the inside and preserves the mucosa and sphincter structures to an extremely high degree.

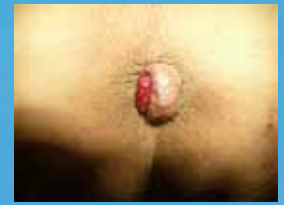The radial and homogenous laser emission required for this procedure results in:

- Tissue reduction in the hemorrhoidal node
- Maximum preservation of muscle, anal canal lining and mucosa
- Restoration of the natural anatomical structure

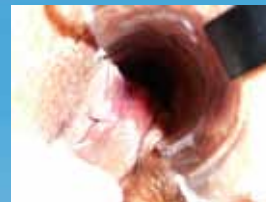suppressed to a high extend improving all subsequent measures to further reduce the symptoms of hemorrhoids.



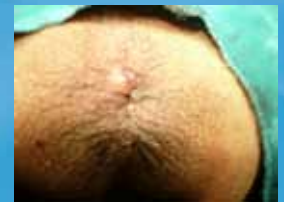Case 1 Pre-OP



Case 2 Pre-OP



Case 1 Post-OP



Case 2 Post-OP



Use of laser hemorrhoidoplasty probe (LHP) enables the endoluminal laser coagulation of both segmental and circular hemorrhoidal nodes.

The controlled emission of laser energy, which is applied to the submucosa, causes the hemorrhoidal mass to shrink. In addition, fibrotic reconstruction generates new connective tissue, which ensures that the mucosa adheres to the underlying tissue. This also prevents the occurrence or recurrence of a prolapse.

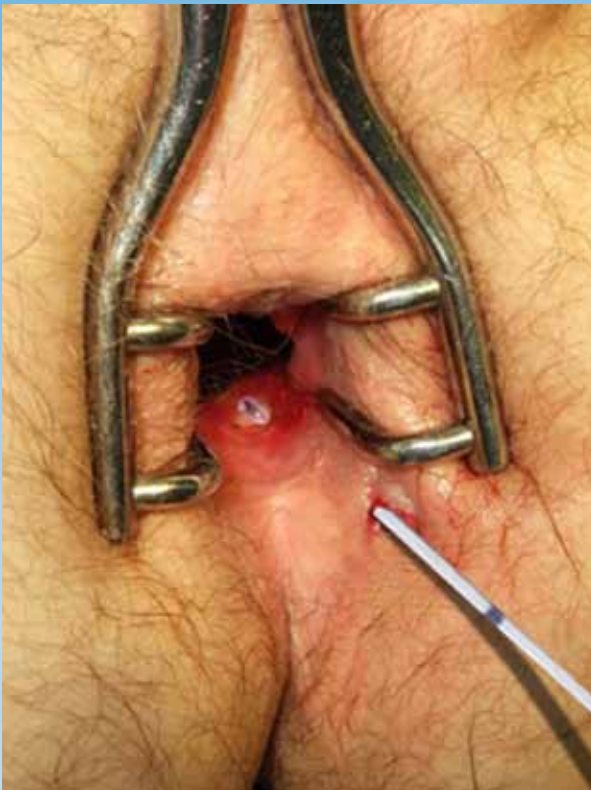No foreign materials (clamps) need to be inserted and, unlike other procedures, LHP is not associated with any risk of stenosis.

Healing is excellent because, unlike conventional surgeries, there are no incisions or stitches. As a result, the patient experiences less post-operative pain and can return to normal activities within a shorter space of time.

- No incisions
- No stitches
- No open wounds

Fistula-tract Laser

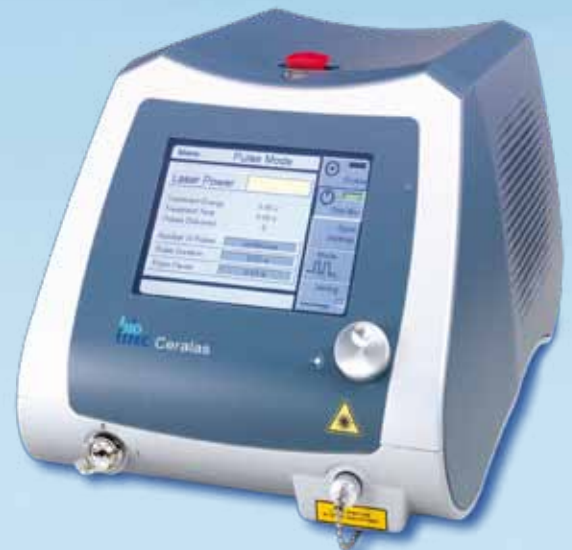Fistula-tract Laser Closure



Advantages:

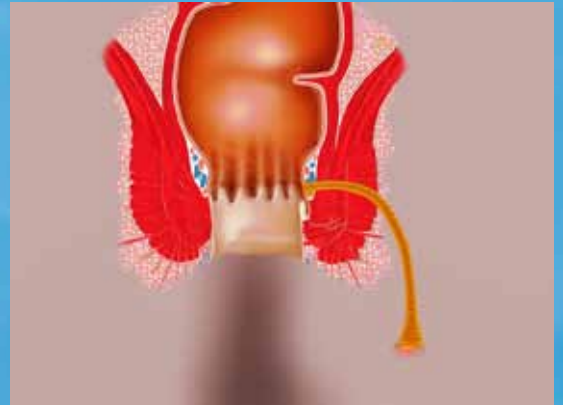- Maximal preservation of the muscle – preservation of continence
- Good control
- No excision or splitting
- Independent on the length of the fistula tract
- Flexible fiber also allows use in convoluted tract
- Can be executed in only a few minutes
- Can be combined with other forms of therapy for closing the osteum

In order to eliminate the fistula tract as gently as possible the flexible, radial emitting laser fiber is inserted from the outside and positioned exactly by using the pilot beam. Defined energy is being emitted radially into the fistula. The epithelialized tissue is being destroyed in a controlled way and the fistula tract collapses. This also supports and accelerates the healing process.

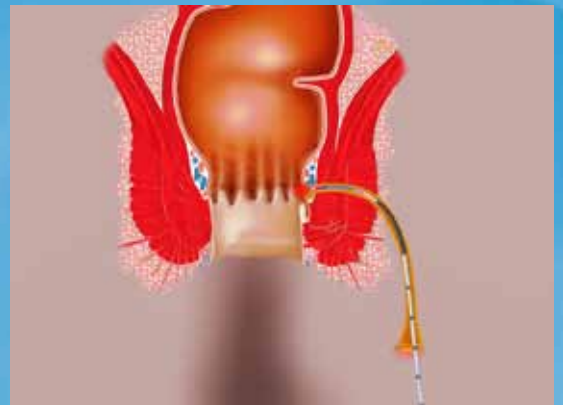

Closure

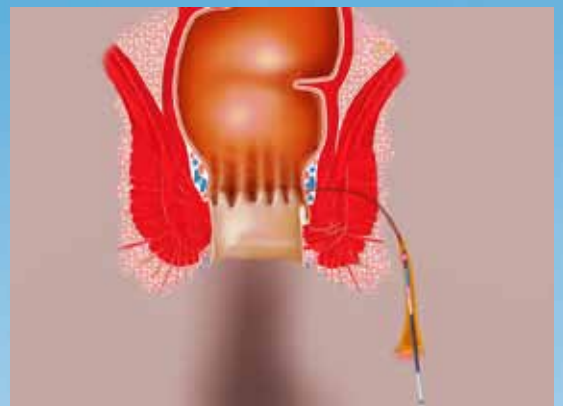
1) After therapy of the abscess and Seton drainage the fistula has epithelised



2) After conventional closure of the internal fistula opening the probe is inserted into the fistula tract



3) Homogeneous application of laser energy radially into the lumen of the fistula. The epithelised tract is destroyed and collapses rear the probe head



FiLaC fiber

The FiLaC fiber applies energy adapted to the pathway of the fistula tract.

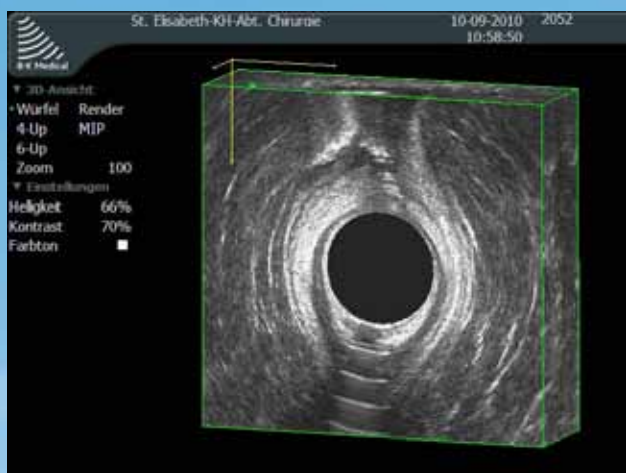
The 360° energy emission ensures homogenous photothermal destruction of the fistula tract, allowing safe closure.

The efficient radiation concept of the FiLaC fiber makes optimal use of the laser energy applied.

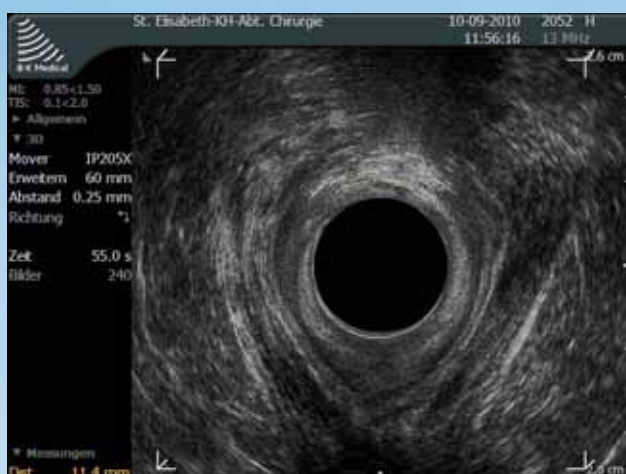Optimal monitoring of the fiber tip is possible thanks to its excellent ultrasound visibility (if applied).

FiLaC

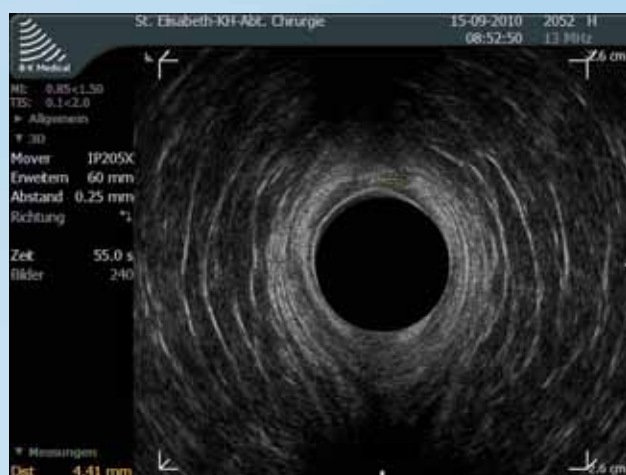Fistula-tract Laser Closure



3-D ultrasound illustration of a trans-sphincteric anal fistula at 12 o'clock (Contrast enhancement via H₂O₂)



Ultrasound image direct after advancement flap. In the area of the former inner opening in the Musculus sphincter ani internus strong echo-reactions can be seen due to the applied laser energy. The protecting flap can be seen as isoechoic zone beneath.



Ultrasound image 5 days post-op. In the treated area the hyperechoic regions are vanished and form a hypoechoic district. The dimensions correlate to the original fistula tract and display the entrance depth of the laser. It also shows the safe application of the laser and short term wound healing.

Literature

FiLaC

Material and Methods:

In a pilot study we operated on 10 (8 male – 2 female) patients. Median age was 51 years (38 – 65 years). There were only cryptoglandular fistulas with either two type 4 and 3, five type 2 and 1 type 1 fistula. All patients had previous surgery due to perianal abscess and fistula up to 6 times prior to definitive surgery. First, all patients had drainage of their perianal abscesses and seton draining of the fistula.

Primarily, the outer and internal opening of the fistula were excised. Following, an advancement flap was prepared, if possible. By applying energy the fistula tract was obliterated under continuous retraction of the laser. At last the flap was placed to cover the former internal opening.

Results

Median follow up was 6.4 months. 8 out of 10 fistulas healed (80 %). One fistula persisted in a patient with a type 4 extrasphincteric fistula and a second one in a patient with a transsphincteric fistula following complicated drainage of a horseshoe abscess. Only one minor form of incontinence (soiling) was observed and no major or minor complications occurred.

Summary

In summary, anal fistula repair using a newly designed radial emitting laser probe in addition to conventional surgery is a very promising original technique in sphincter preserving anal fistula repair. The observed healing rates along with the results for postoperative continence were excellent. No complications have been observed.

Dr. Arne Wilhelm, submitted in Techniques in Coloproctology

HeLP™

Clinical proven:

Patients and methods:

In the past three years, 200 patients were treated with Doppler-guided laser photocoagulation of hemorrhoidal arteries. In all cases, treatment was performed on an outpatient basis and anaesthesia or analgesia was not necessary.

Results: Mild intra- and postoperative complications were seen. 91 % of the patients show an improvement of hemorrhoidal symptoms 1 to 12 months after treatment.

Conclusion:

Doppler-guided laser photocoagulation of hemorrhoidal arteries is a good and safe method for the ambulatory treatment of hemorrhoids.

Raffaele Salfi, coloproctology 2009;31:99-103

LHP

Patients and methods

In the period between 01/2006 and 10/2009 a total of 332 patients were operated with this method by using a 980nm diode laser. Hemorrhoidal tissue is being destroyed submucosally by a special radial emitting fiber. The vascular convolute is made desolate and there is fibrotization of the tissue. On some of the patients in addition to interstitial irradiation of the cushions mucopexy of all segments was done.

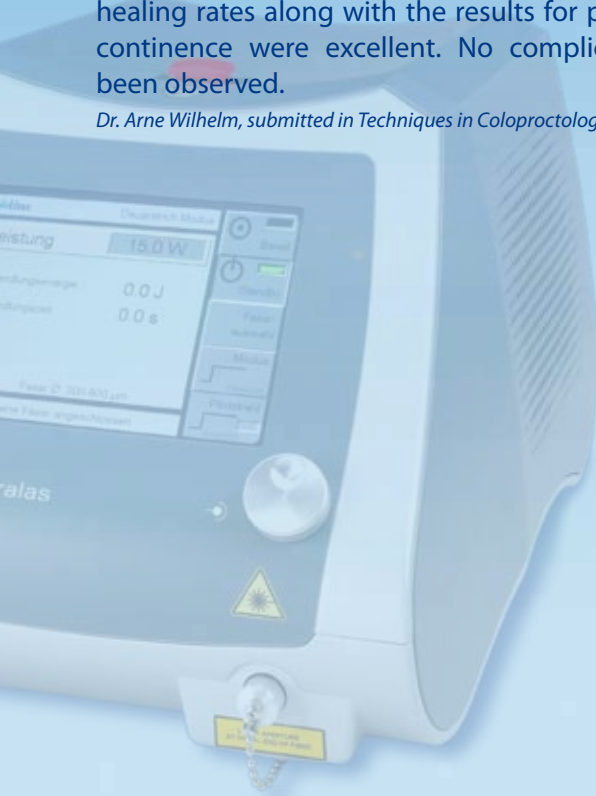Results

The operation executed under day surgical circumstances in lithotomy position took an average of 17.4 min for all three segments (from inserting the proctoscope to applying the tamponade). The average period of disability with the LHP method was 4.2 days and in combination with mucopexy 7.4 days. Within the post-operative follow-up period of 6-36 months a prolapsed node could be found in 5.8% of all patients examined (one or more 2nd degree nodes).

Conclusion

The LHP method represents another alternative for existing methods. The complication and recurrence rates as well as operating time are not longer compared to conventional techniques. Especially the work mode which preserves the anoderm and reduces hemorrhoidal tissue painlessly and without many complications is of a big advantage. The mucous membrane remains intact and the natural anatomy can be restored.

Dr. A. Karahaliloglu, coloproctology 2010, 32:116-123



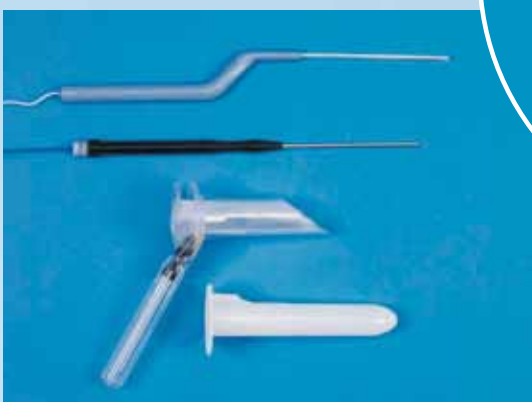HeLP™

System

Other possible proctological applications of this laser procedure:


- Sinus pilonidalis
- Skin tags
- Removal of polyps
- Condyloma
- Fissures

The HeLP™ platform comprises a Ceralas laser including a high-frequency Doppler (20 MHz) for assessing hemorrhoidal artery position, and specially designed HeLP™ procedure kits, which includes all equipment needed to carry out these treatment options.



FiLaC™

Hardware & Accessories



Article description	Item number
Doppler assisted laser ligation of the arteries	
HeLP™ Dopplertransceiver	AB2530
HeLP™ Procedure Kit HeLP™ Proctoscope with Working Channel HeLP™ Doppler Probe HeLP™ Laser Fiber with Handpiece	502400510
Laser hemorrhoidoplasty	
Ceralas LHP-Fiber incl. Handpiece	501100210
LHP Procedure Kit (consisting of LHP fiber + single use proctoscope)	501100220
Universal Handpiece	
Universal biolitec Dual Luer Lock Handpiece	AB2517
Fistula-tract Laser Closure	
FiLaC Probe	501100250



biolitec AG

Otto-Schott-Str. 15 · 07745 Jena, Germany
Phone: +49 3641 519 53 0 · Fax: +49 3641 519 53 33
E-Mail: info@biolitec.de · <http://www.biolitec.de>

biolitec Italia SRL

Viale Monza 133 · 20129 Milano, Italy
Phone: +39 02 28 17 2 400 · Fax: +39 02 28 17 2 299
E-Mail: info@biolitec.it · <http://www.biolitec.com>

biolitec Inc.

515 A Shaker Road · East Longmeadow, MA 01028, USA
Phone: +1 413 5 25 06 00 · Fax: +1 413 5 25 06 11
E-Mail: info@biolitec.com · <http://www.biolitec.com>

biolitec (M) Sdn. Bhd.

No. 18, Jalan PJS. 7/21 · Bandar Sunway · 46150 Petaling Jaya, Selangor D.E., Malaysia
Phone: +603 56 32 71 28 · Fax: +603 56 38 01 28
E-Mail: info@biolitec.com.my · <http://www.biolitec.com>

biolitec India Pvt. Ltd.

603/604, 6th Floor · Carlton Towers, Airport Road, Bangalore - 560 008, India
Phone: +91 80 41 26 23 94 · Fax: +91 80 41 15 35 05
E-Mail: mohan.chinny@biolitec.com · <http://www.biolitec.com>

biolitec FZ LLC

B/P 49 Unit 306 · Dubai Healthcare City · Dubai, UAE
Phone: +971 4 4298 592 · Fax: +971 4 4298 591
E-Mail: detlev.berndt@biolitec.com · <http://www.biolitec.com>

biolitec SIA

Kaniera iela 10a · Riga, LV-1063, Latvia
Phone: +371 65 34 36 46 · Fax: +371 65 30 76 78
E-mail: info.lv@biolitec.com · <http://www.biolitec.com>

CeramOptec GmbH

Siemensstraße 44 · 53121 Bonn, Germany
Phone: +49 228 97 96 70 · Fax: +49 228 97 96 799
E-Mail: info@ceramoptec.de · <http://www.ceramoptec.de>

www.biolitec.de